

Pereira, Agostinho Oliveira


Scan Type: Fast Macular Thickness Map OS

Scan Date: 3/18/2013

DOB: 7/9/1952, ID: 14760, Male

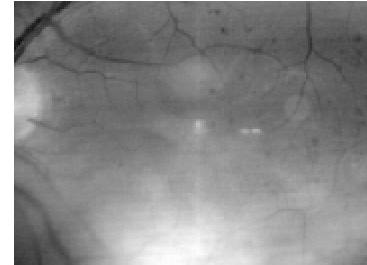Scan Length: 6.0 mm

OCT Image

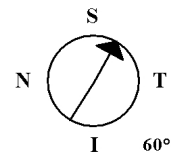
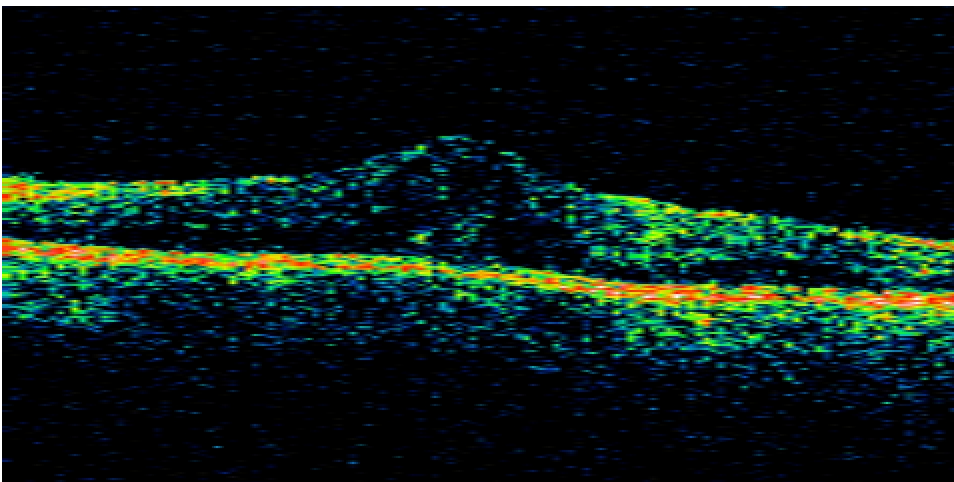


Signal Strength (Max 10)	5

Fundus Image



Scanned Image



Signature:

\_\_\_\_\_  
\_\_\_\_\_

Physician:

Leite & Leite - Microcirurgia Ocular Lda